

Case 12

You are an F2 working in the emergency department at General Hospital. Your consultant is Dr Bain.

Your bleep number is 1789

Patient name: Joseph Delacroix

Date of birth: 5th May 1964

Patient number: X543109675

Mr Delacroix is admitted to the emergency department with central crushing chest pain, radiating into his left arm, which started 2 hours previously. He is pale, sweaty and has vomited once during transfer.

His past medical history includes hypertension and stable angina. He has a thirty-pack-year smoking history.

On examination airway is patent and both lungs are clear on auscultation. Heart sounds I – II + 0. Capillary refill time <3 seconds. Abdomen soft and non-tender.

Investigations

Pulse	79 beats per minute
Blood pressure	142/94 mmHg
Respiratory rate	28 breathes per minute
Oxygen saturations	94% (room air)
Temperature	36.4 degrees Celsius

Chest x-ray and routine blood tests pending.

ECG results are below:

Task

Please report and interpret the results of the ECG on hospital notepaper. Comment on the rate, rhythm, axis, P waves, PR interval, QRS complex, T waves, ST segment and QT interval.

Make sure to include the most likely diagnosis and what the next steps in management should be.

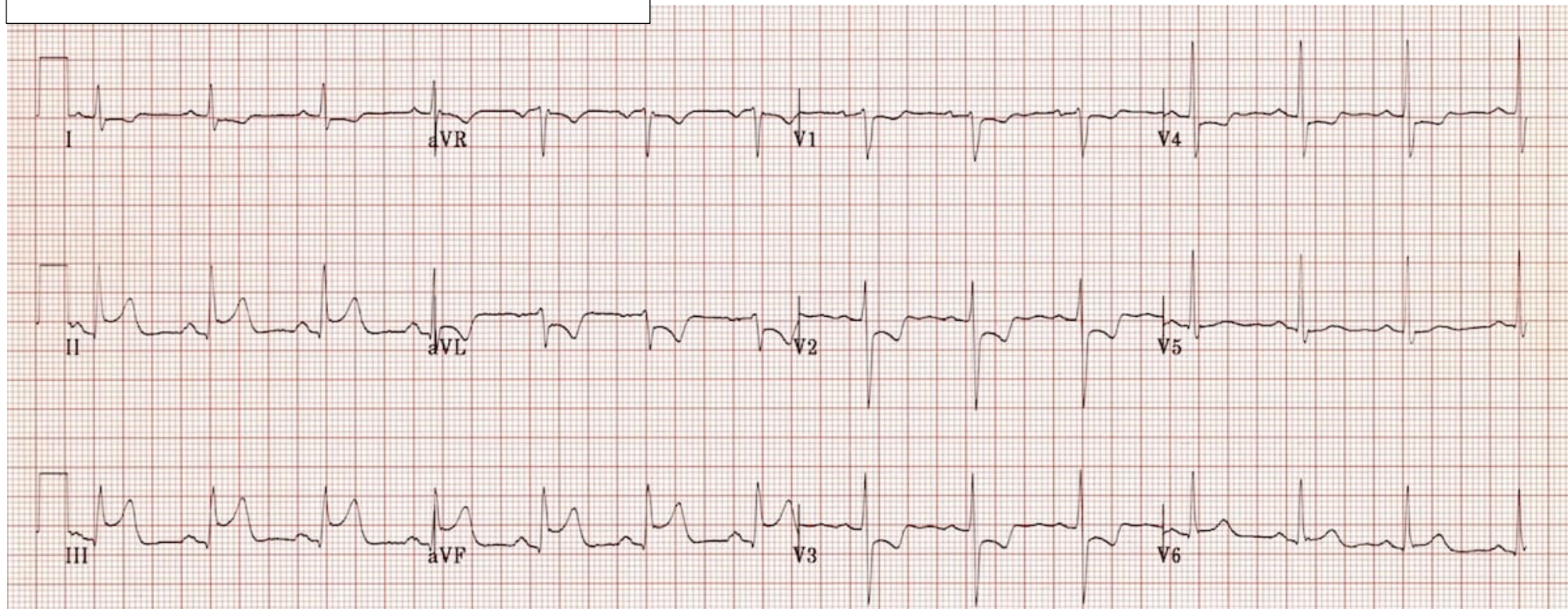
Patient: Joseph Delacroix

DOB: 05/03/1964 Hospital #: X543109675

Time: 09:50 Date: 22/03/2023

Paper speed 25mm/sec. Calibration 10mm/mV

QT/QTc: 350ms/426ms



Ward:

Date of birth:

Hospital number:

[illegible]