

Case 16

You are the Foundation Year 1 doctor on Gastroenterology at General Hospital.

Your bleep number is 7560 and your GMC number is 49910.

The consultant is Dr Gooding.

Patient details

Patient name: Joanne Carter

Date of birth: 14th March 1933

Patient number: X859143910

History

Joanne Carter was admitted to the gastroenterology ward yesterday due to difficulty swallowing leading to malnutrition and dehydration. Mrs Carter is currently being treated with chemotherapy for oesophageal cancer. She has been assessed by the speech and language team who have determined that her swallow is unsafe and that she is at risk of choking and aspiration.

This is communicated to the patient by Dr Gooding and it is decided that a nasogastric tube should be inserted and enteral feeding commenced.

The NG tube is inserted but there is no aspirate.

An AP chest x-ray is recorded, which is shown below:

Patient: Joanne Carter

DOB: 14/03/1933 Hospital #: X859143910

Time: 09:50

Date: 28/03/2023

Position: AP

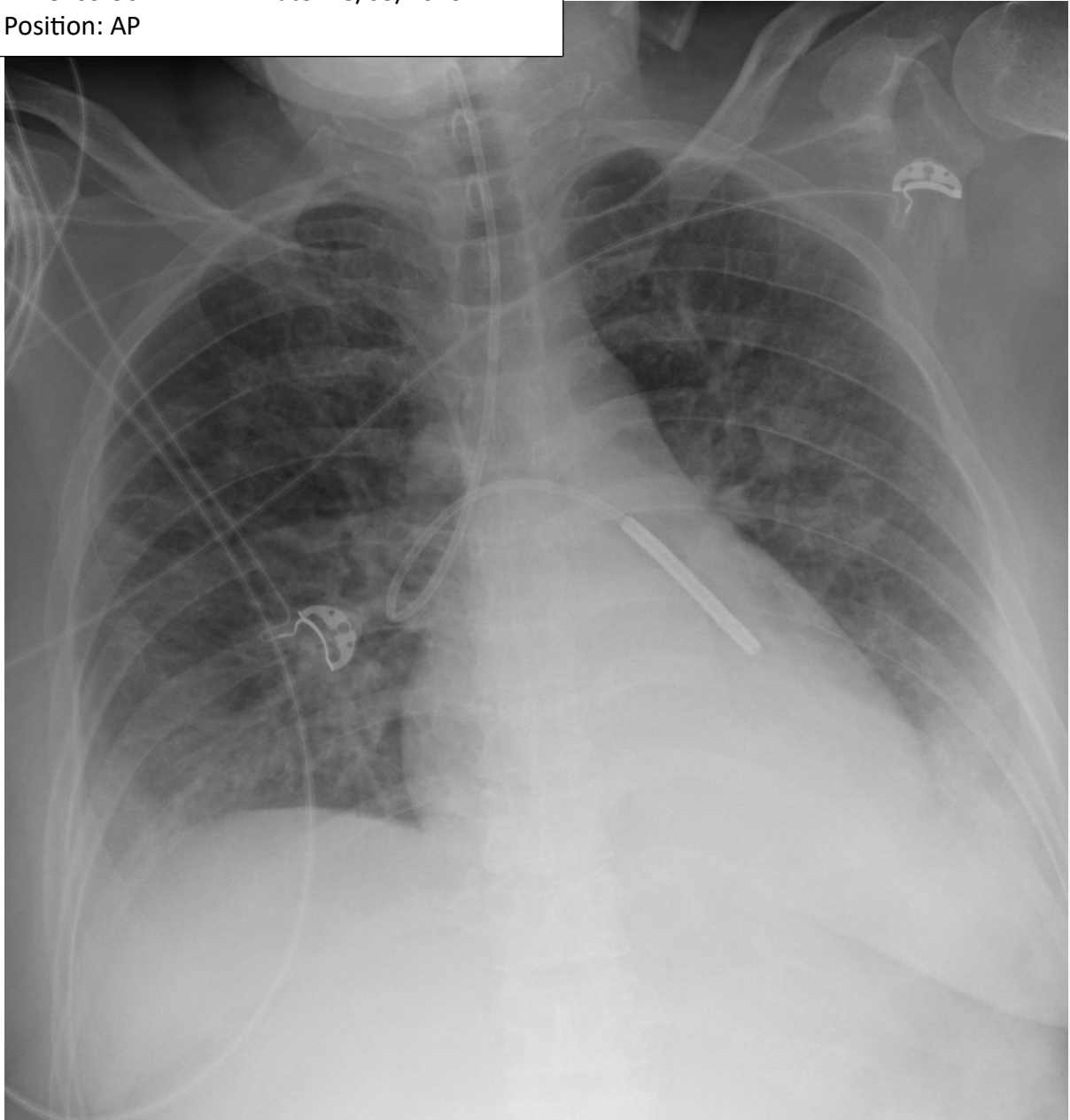


Image courtesy of Frank Gaillard, Radiopaedia.org, rID: 32358

Task

Please report the chest radiograph on hospital notepaper, focussing on the position of the nasogastric tube. Comment on whether it is safe to begin enteral feeding and justify your decision.

